
CLINICAL REPORT

The Use of Cerebral Oximetry as a Monitor of the Adequacy of Cerebral Perfusion in a Patient Undergoing Shoulder Surgery in the Beach Chair Position

Gregory W. Fischer, MD*; Toni M. Torrillo, MD[†]; Menachem M. Weiner, MD[†];
Meg A. Rosenblatt, MD[‡]

*Anesthesiology and Cardiothoracic Surgery, Mount Sinai School of Medicine, New York, New York; [†]Anesthesiology, Mount Sinai School of Medicine, New York, New York;

[‡]Anesthesiology and Orthopedics, Mount Sinai School of Medicine, New York, New York, U.S.A.

■ **Abstract:** Four cases of ischemic injury have been reported in patients undergoing orthopedic surgery in the upright position. We describe the use of cerebral oximetry as a monitor of the adequacy of cerebral perfusion in a 63-year-old woman who underwent arthroscopic rotator cuff surgery in a beach chair under general anesthesia. During positioning, a decrease in blood pressure was accompanied by a decrease in cerebral oxygen saturation ($S_{ct}O_2$) and was treated with phenylephrine. When spontaneous ventilation resumed, an increase in end-tidal carbon dioxide was accompanied by an increase in $S_{ct}O_2$. Cerebral oximetry may prove useful as a guide monitor and manage nonsupine patients. ■

Address correspondence and reprint requests to: Meg A. Rosenblatt, MD, Associate Professor of Anesthesiology and Orthopedics, Mount Sinai School of Medicine, Department of Anesthesiology, Box 1010, One Gustave L Levy Place, New York, NY 10029, U.S.A. E-mail: meg.rosenblatt@mounsinai.org.

Submitted: December 20, 2008; Final revision accepted: February 13, 2009

DOI: 10.1111/j.1533-2500.2009.00282.x

Key Words: cerebral oximetry, beach chair position

INTRODUCTION

Four cases of ischemic brain injury were reported to have occurred in patients undergoing orthopedic surgery in the upright position.¹ When two of them were recently highlighted,² multiple responses regarding the ideal way to ensure adequate cerebral perfusion, especially in the setting when blood pressures are not measured at the level of the external auditory meatus, were generated.³⁻⁶ We report the novel use of cerebral oximetry to both monitor cerebral oxygen saturation ($S_{ct}O_2$) and to guide interventions.

CASE REPORT

A 63-year-old woman (154 cm, 51 kg) was scheduled to undergo recurrent arthroscopic right rotator cuff surgery. She requested general anesthesia without a supplementary interscalene block because of a previous traumatic experience. Her past medical history was significant for idiopathic thrombocytopenic purpura

treated with steroids and splenectomy, coronary artery disease, complicated by myocardial infarction and chronic rheumatic arthritis. Additionally, she had hypothyroidism, gastroesophageal reflux, and elevated cholesterol. Her medications included levothyroxine, prednisone, aspirin, pantoprazole, and ezetimibe.

She was brought to the operating room where standard American Society of Anesthesiologists monitors were applied. After preoxygenation, general anesthesia was induced with propofol 200 mg and muscle paralysis obtained utilizing succinylcholine 100 mg. Her airway was secured uneventfully with a standard cuffed 7.0 mm internal diameter endotracheal tube. The patient was mechanically ventilated in a volume-controlled mode with tidal volumes of 8 mL/kg and an adjustable respiratory rate in order to obtain end-tidal carbon dioxide (EtCO₂) values between 30–35 mm Hg. Noninvasive blood pressure monitoring was achieved via a left arm cuff. In addition, bilateral cerebral oximetry probes were placed on her forehead for continuous monitoring of cerebral tissue oxygen saturation (S_{ct}O₂) (FORE-SIGHT®, CAS Medical Systems Inc., Branford, CT, U.S.A.). After raising the back of the beach chair to 80°, we measured the patient's external auditory meatus to be 30 cm above the level of the cuff. Thus, all mean arterial pressures (MAPs) recorded would be approximately 20 mm Hg greater than those at the head. We decided that all MAPs < 70 mm Hg (in the arm) would be treated with phenylephrine boluses of 80 µg, with the intent to maintain adequate cerebral perfusion pressure. Additionally, any decrease in S_{ct}O₂ < 55% would trigger the same intervention.

Anesthesia was maintained with sevoflurane (end-tidal: 0.8–1.2 Vol%) and intermittent boluses of fentanyl. The S_{ct}O₂ ranged from 49% to 86% (left and right S_{ct}O₂ values were within ±8% of each other throughout). The initial average supine S_{ct}O₂ was 65%. Post-intubation, the S_{ct}O₂ increased to an average value of 78%. After elevating the back of the beach chair, the patient became hypotensive (MAP < 70 mm Hg), which coincided with a rapid decline in S_{ct}O₂ (left S_{ct}O₂ 49%). This was treated with a phenylephrine bolus resulting in a normalization of both S_{ct}O₂ and MAP. During the course of the procedure, 11 additional boluses of phenylephrine were administered for hypotension and/or decreased S_{ct}O₂ values. Figure 1 reveals a direct relationship between blood pressure and S_{ct}O₂. One hour after induction, the patient was allowed to breath spontaneously resulting in an increase in EtCO₂ to 40–45 mm Hg, without a significant change in MAP,

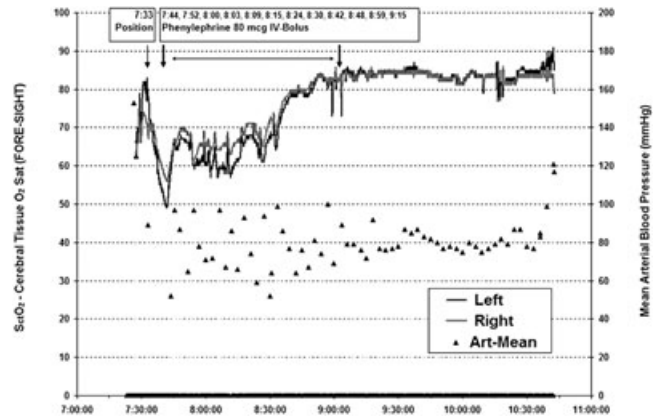


Figure 1. S_{ct}O₂ and noninvasive mean arterial pressures (MAPs) during the procedure. Multiple boluses of phenylephrine were administered which correlated with improvements of MAPs and increased S_{ct}O₂ values.

which in turn led to an increase in S_{ct}O₂ (>80%) and stabilization of hemodynamics for the rest of the case.

Upon completion of the procedure, sevoflurane was discontinued and the patient awoke and her trachea was extubated uneventfully. Although no specific psychometric tests were performed, the patient reported no neurologic deficits on the first postoperative day.

DISCUSSION

The brain consumes approximately 20% of the body's oxygen delivery. Catastrophic failure to provide sufficient oxygen (eg, stroke, cardiac arrest) results in debilitating brain injury. As a result, it is of paramount importance for the perioperative care provider to recognize cerebral ischemia early, and once detected, to immediately restore adequate perfusion. Currently, brain oxygenation can be measured invasively by jugular bulb oximetry (S_{iv}O₂) or brain tissue pO₂ sensors.^{7,8} However, these modalities are invasive and difficult to use. Cerebral oximetry is a noninvasive monitor that provides measurements of cerebral oxygenation, and has been used extensively in cardiac anesthesia to detect cerebral hypoxia and ischemia during cardiopulmonary bypass.^{9,10} Cases of cerebral ischemia in patients undergoing surgical procedures in the sitting position have occurred and we report the first use of cerebral oximetry to detect, and potentially, prevent cerebral ischemia in such clinical scenarios.

Systemic MAPs between 50–150 mm Hg are generally considered to lie within the range of cerebral autoregulation.¹¹ Although it may be tempting to say that MAP is an adequate reflection of cerebral perfusion, it is

important to realize that these boundaries are not fixed. Chronic hypertension shifts these limits of autoregulation toward higher blood pressure levels and thus, the lower boundary of autoregulation is unknown. Accepting blood pressure values that are beneath the range of autoregulation could potentially lead to unrecognized cerebral ischemia. Without a history of arterial hypertension, we assumed a normal range of autoregulation for our patient, so a corrected MAP of 50 mm Hg was chosen as a threshold for intervention. But since currently there is no available way of identifying the inflection point in the autoregulative curve, where the cerebral perfusion goes for pressure dependant to independent, monitoring $S_{ct}O_2$ reflects the end-effect of this autoregulative process (tissue oxygenation) and offers objective data upon which therapeutic interventions can be made.

An acceptable $S_{ct}O_2$ threshold under which a corrective intervention should occur has yet to be defined. We decided to use $S_{ct}O_2$ 55% as our intervention threshold for the following reasons. First, the utilization of $S_{iv}O_2$ measurements as a marker for global cerebral ischemia/metabolism is recognized and has been shown to correlate with impaired postoperative neurocognitive dysfunction once a value of 45% had been breached for prolonged periods of time.¹² The larger the difference between S_aO_2 and $S_{iv}O_2$, the more oxygen is extracted from the cerebral tissue, in other words the higher the metabolic demand. Second, it is estimated that cerebral oximeter interrogated brain tissue microvasculature is about 70% venous and 30% arterial during most physiological conditions in humans based on positron emission tomography studies.¹³ As a consequence of this distribution, the absolute measured $S_{ct}O_2$ is about 10% higher than $S_{iv}O_2$ consistently over a wide range of oxygen saturation values. In other words, $S_{ct}O_2$ can be used as a marker of cerebral metabolism at the microvasculature level. The lower the number, the higher the metabolic rate. The FORE-SIGHT measured $S_{ct}O_2$ is about 10% higher than $S_{iv}O_2$, consistently, over a wide range of oxygen saturation values.^{14,15} Therefore, we chose the $S_{ct}O_2$ threshold for cerebral ischemia, which in turn would mandate the same intervention as for arterial hypotension, to be 55%. We know that the content of oxygen in blood is primarily determined by hemoglobin concentration and oxygen saturation, but once a p_aO_2 value of 100 mm Hg is exceeded, increasing the FIO_2 plays only a minor role in improving the degree of oxygenation.

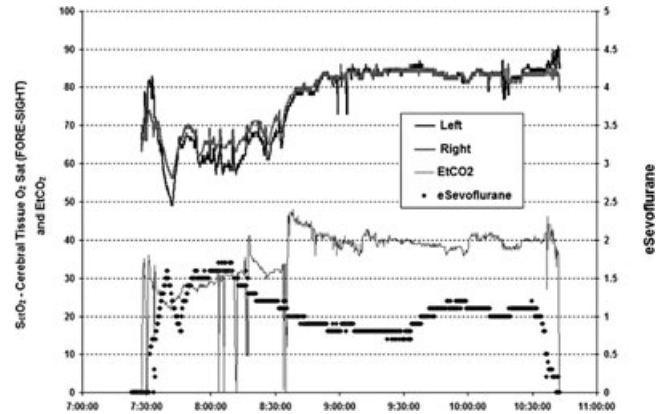


Figure 2. $S_{ct}O_2$, end-tidal sevoflurane (eSevoflurane) and end-tidal carbon dioxide (EtCO₂) during the procedure. There is a direct correlation between EtCO₂ and $S_{ct}O_2$. Improvement in $S_{ct}O_2$ and hemodynamic stability occur with the resumption of spontaneous ventilation and accompanying elevated CO₂ values.

Interestingly, we observed causality between EtCO₂ and $S_{ct}O_2$ (Figure 2). After allowing the patient to breathe spontaneously, we observed a much more stable course in regards to $S_{ct}O_2$ and arterial blood pressure. Arterial p_aCO_2 has a near linear relationship with cerebral blood flow (for every 1 mm Hg increase in p_aCO_2 , an increase of 2% to 4% in cerebral blood flow is seen), making it one of the most important regulators of cerebral blood flow.¹⁶ The FORE-SIGHT cerebral oximetry monitor calculates total hemoglobin concentration in tissue by the following equation:

$$\text{TotalHb} = \text{HbO}_2 + \text{Hb}$$

TotalHb is, therefore, proportional to hemoglobin or blood hematocrit and decreases during hemodilution. A rise in TotalHb can be expected if red blood cells are transfused resulting in an increase of blood hematocrit. Additionally, TotalHb is also sensitive to autoregulatory mechanisms within the vasculature. Increased blood vessel diameter in response to acidosis, potassium concentration or CO₂ partial pressure will result in an increased hemoglobin concentration in tissue, which will result in an increase in TotalHb. Usually an increase in cerebral blood flow from hemodynamic changes such as increased cardiac output will increase TotalHb as well. A decrease in cerebral perfusion because of low cardiac output, circulatory arrest, clamping of major cerebral blood vessels, or low perfusion pressure can all result in a decrease in TotalHb. This is of clinical interest, because it suggests that spontaneous respiration could potentially be protective, making regional anes-

thetia with mild sedation the anesthetic technique of choice for surgeries performed in the sitting position, or if using general anesthesia is chosen, the clinician should allow normal to slightly elevated EtCO₂.

In summary, sporadic reports of unanticipated cerebral ischemic events have shown that arterial blood pressure monitoring alone cannot guarantee adequate cerebral perfusion. Additional monitoring may potentially prevent devastating outcomes. Cerebral oximetry may prove useful as a monitor for cerebral ischemia and to guide clinical interventions in nonsupine patients, and we described its first use in such a clinical scenario. Further studies are indicated to confirm the usefulness of cerebral oximetry in nonsupine patients.

REFERENCES

1. Pohl A, Cullen DJ. Cerebral ischemia during shoulder surgery in the upright position: a case series. *J Clin Anesth.* 2005;17:436.
2. Cullen DJ, Kirby RR. Beach chair position may decrease cerebral perfusion. *ASPF.* 2007;22:25–27.
3. Munis J. The problems of posture, pressure, and perfusion. *APSF.* 2008;22:82–83.
4. Budnyk S. To the editor. *APSF.* 2008;22:81.
5. Cucchiara R. To the editor. *APSF.* 2008;22:81.
6. Cullen DJ, Kirby RR. Hazards of the beach chair position explored. *APSF.* 2008;22:81.
7. al-Rawi PG, Hutchinson PJ, Gupta AK, Piechnik SK, Pickard JD, Kirkpatrick PJ. Multiparameter brain tissue monitoring—correlation between parameters and identification of CPP thresholds. *Zentralbl Neurochir.* 2000;6:74–79.
8. Jödicke A, Hübner F, Böker DK. Monitoring of brain tissue oxygenation during aneurysm surgery: prediction of procedure-related ischemic events. *J Neurosurg.* 2003;98:515–523.
9. Murkin JM, Adams SJ, Novick RJ, et al. Monitoring brain oxygen saturation during coronary bypass surgery: a randomized, prospective study. *Anesth Analg.* 2007;104:51–58.
10. Fischer GW. Recent advances in application of cerebral oximetry in adult cardiovascular surgery. *Semin Cardiothorac Vasc Anesth.* 2008;12:60–69.
11. Steiner LA, Andrews PJ. Monitoring the injured brain: ICP and CBF. *Br J Anaesth.* 2006;97:26–38.
12. Croughwell ND, Newman MF, Blumenthal JA, et al. Jugular bulb saturation and cognitive dysfunction after cardiopulmonary bypass. *Ann Thorac Surg.* 1994;58:1702–1708.
13. Ito H, Kanno I, Fukuda H. Human cerebral circulation: positron emission tomography studies. *Ann Nucl Med.* 2005;19:65–74.
14. MacLeod DB, Ikeda K, Keifer JC, Moretti E, Ames W. Validation of the CAS Adult Cerebral Oximeter during Hypoxia in Healthy Volunteers. *Anesth Analg.* 2006;102:S162.
15. MacLeod DB, Ikeda K, Moretti E, Keifer JC, Grocott H. Using the CAS cerebral oximeter to estimate cerebral venous oxygen saturation. Presented at the ASA 2005; 2005.
16. Vavilala MS, Lee LA, Lam AM. Cerebral blood flow and vascular physiology. *Anesthesiol Clin North America.* 2002;20:247–246.